

An Ingenious Modification in Conventional Swing Lock Cast Partial Denture for Rehabilitating A Hemi Mandibulectomy Defect

RUPAL JAYDIP SHAH¹, SANJAY BALAJI LAGDIVE², SHRADDHA LALIT SAINI³, VISHAL BIPINBHARI VERMA⁴, SATYAPRAKASH RANJIT SHAH⁵

ABSTRACT

Mandibular resections compromise the balance and symmetry of mandibular functions. Since centuries there has been advent of various prosthetic treatment modalities to improve the masticatory efficiency. Swing lock dentures, a treatment facet with high degree of clinical effectiveness, yet gradually fading into oblivion due to its design complexities, has been resurrected by retaining its indigenous concept of reciprocation, and consolidating aesthetics with introduction of newer breed of aesthetic material (Thermoplastic Acetal resin).

Keywords: Acetalic resin, Maxillofacial resurrection, Segmental mandibulectomy

CASE REPORT

A 16-year-old female was referred to the Department of Prosthodontics for prosthetic rehabilitation of the left sided resected mandibular defect. She had been previously treated in oral surgery department of the same institution where she had presented a year ago with a large asymptomatic swelling associated with left lower posterior teeth. It was diagnosed as an Ameloblastoma on histopathological and radiological examination. Orthopantomogram (OPG) revealed that surgical resection was carried out along with placement of iliac crest graft and Titanium reconstructive plates [Table/Fig-1].

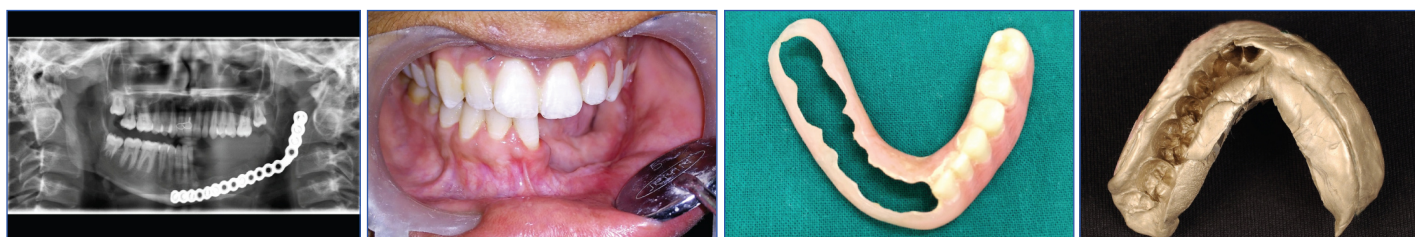
On referral to prosthodontic department patient was clinically healthy with healed surgical site. On extraoral examination there was slight bulging of lower left cheek portion due to bulk of reconstructive plates. Mouth opening was not restricted and no deviation of mandible was noted. Intraoral examination revealed the oral hygiene to be fair, with no noted derangement in occlusion [Table/Fig-2]. Maxillary arch was completely dentate and in the mandibular arch tooth #41-48 were present in good condition. The left lower region which borne the surgical site, presented with Cantor and Curtis type IV classification [1], had compromised denture bearing area, hence, a conventional removable denture could not serve the prosthodontic rehabilitation efficaciously. Other treatment modalities like implants were not considered due to economical constraints. Upon contemplating the array of treatment options available, the fabrication of a "modified" swing lock cast partial denture was finalized as the prosthesis of choice.

Procedure

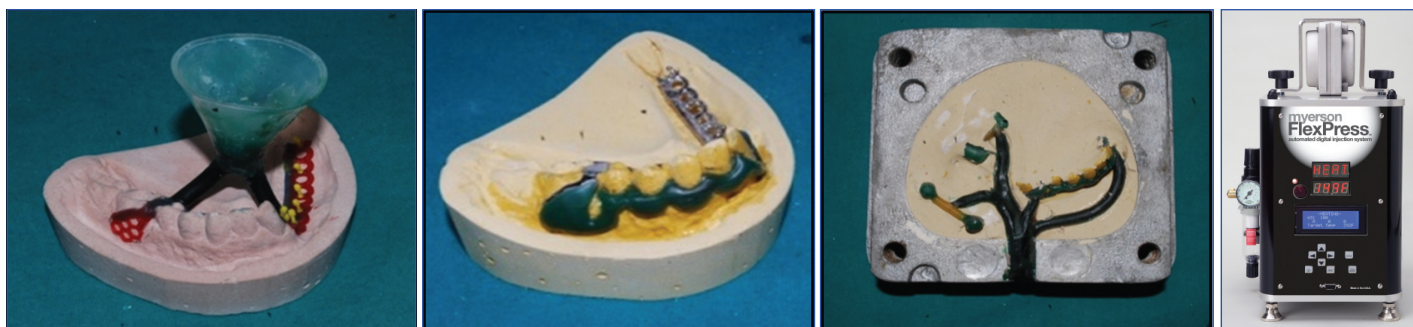
Before proceeding with swing lock denture fabrication, as an interim manoeuvre, a treatment partial denture (gum stripper) with labial acrylic bar was delivered to the patient, so as to acclimatize the patient for the definitive prosthesis, since the patient did not

have a previous denture experience [Table/Fig-3]. Furthermore aesthetic verification of the labial Acetal framework could be ensured with this interim prosthesis.

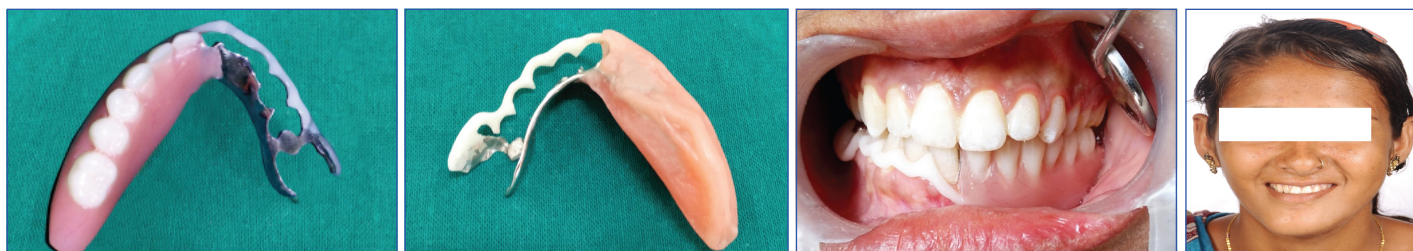
On follow up, patient was not satisfied with the fit of the denture that followed commencing with the modified swing lock denture fabrication as definitive prosthesis. Preliminary impressions of both upper and lower arches were made with irreversible hydrocolloid (MprESSIX Alginate, Dentsply Sirona, Dentsply) and poured with type II dental stone. Diagnostic casts obtained were surveyed and designed to determine the position of occlusal rests, guiding planes and necessary alterations in mouth. Following teeth preparation for rest seats on tooth #45 (distal rest) #46 (mesial rest), final impression was made using "functional" impression technique. An individualized full arch custom tray was first fabricated with autopolymerising resin (Ashwin, Super Dental Products, Delhi, India), followed by verifying their correct extensions, and sequentially border moulded using low fusing impression compound (DPI Pinnacle tracing sticks). This recorded the labial, buccal and lingual tissue contours of the ipsilateral left sided post resection unyielding soft tissues in a functional state. A final pick-up impression was recorded using medium body polyvinyl siloxane impression material (Affinis, Coltene Whaledent, Addition silicone, Switzerland) [Table/Fig-4]. It ensured a maximally extending impression being obtained, within harmonious tolerance of the peripheral tissues physiological limits [2,3]. Final impression was poured with type IV stone (Kalrock, Kalabhai Karson Pvt. Ltd., Mumbai, India). Wax pattern framework was designed and cast with cobalt- chromium alloy (Vitallium; Dentsply, USA) [Table/Fig-5]. Metal framework was verified in patient's mouth for proper seating and adjusted accordingly. In the laboratory wax pattern framework for the labial portion was made separately [Table/Fig-6] and Acetal resin (DURACETAL) was injected through injection moulding technique [Table/Fig-7] using



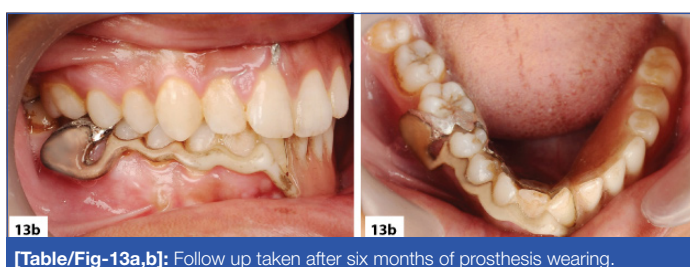[Table/Fig-1]: Orthopantomograph showing the iliac crest graft with reconstructive plate. [Table/Fig-2]: Post operative intraoral view of the resected mandibular defect. [Table/Fig-3]: An interim treatment partial denture delivered to patient. [Table/Fig-4]: Final impression made using functional impression technique. (Images left to right)



[Table/Fig-5]: Spruing of wax pattern for fabrication of cast partial framework. [Table/Fig-6]: Wax pattern separately prepared for Acetal resin wrap around design. [Table/Fig-7]: DuraCetal injected through injection moulding technique. [Table/Fig-8]: The myerson flex press. (Images left to right)



[Table/Fig-9,10]: The final processed modified Swing lock denture with labial Acetal bracing design (cameo and intaglio surfaces respectively). [Table/Fig-11]: Prosthesis seated intraorally into patient's mouth. [Table/Fig-12]: Post insertion of prosthesis with patient's gratifying smile of satisfaction. (Images left to right)



[Table/Fig-13a,b]: Follow up taken after six months of prosthesis wearing.

MYERSON FLEX PRESS [Table/Fig-8]. After try-in of the entire framework, maxillo-mandibular relationship was recorded. An artificial tooth arrangement was done to obtain unilateral balanced occlusion, and try-in was successfully verified. Thereafter, denture was processed and finished.

The final denture thus consisted of a fused locking between the Acetal resin and the metal portion of the removable partial denture that formed a bracing effect around the cervices of natural dentition [Table/Fig-9,10]. Specific emphasis was laid upon for achieving a reasonably durable bond between the cast metal framework and wrap around designed Acetal bracing labial bar, which was precisely "mechano-chemical" in nature. This is because of the reason that it is extremely difficult to achieve true adhesion to Acetal by virtue of its chemical inertness. The cast metal framework was initially degreased, and was then surface treated by means of Shot Blasting abrasion, so as to create mechanical irregularities and corrugations favourable to bond with Acetal. The Acetal component on the other hand was subjected to surface treatment by applying cyanoacrylate adhesive, to combat its inertness and generate surface reactivity to metal framework [4]. The final prosthesis was seated intraorally [Table/Fig-11, 12] and was evaluated on grounds of fit of the denture, occlusal interferences and impingement of the denture on soft- tissues. Patient was educated for the insertion and removal of the prosthesis and maintenance of oral hygiene. Follow-up was carried out at scheduled intervals of 24 hours, one week, three weeks, two months and six months [Table/Fig-13a,b]. Patient expressed increased comfort with the timely follow up visits, without any notable complaint.

DISCUSSION

Rehabilitation of mandibular resected cases present a daunting task to the prosthodontists, as compared to maxillary defects, as they yield greater functional impairments, namely defective

speech articulation, difficulty in swallowing, deviation of mandible during functional movements, poor control of salivary secretions and severe cosmetic disfigurement. Thereby, successful holistic rehabilitation requires the skills and expertise of a specialist maxillofacial prosthodontist who understands the basic needs and expectations of the patient.

This case report entails the rehabilitation of a hemi-mandibulectomy patient with a modification in the design of swing lock denture, retaining its inherent concept of reciprocation, achieved through a lingual plate that contacts all of the teeth by the projection of labial bar, along with incorporation of a newer breed of material - thermoplastic Acetal resin to integrate the quality of retention and support with aesthetics. Basic design of a classical swing-lock prosthesis incorporates all the design principles of a conventional cast partial denture with its "swing lock" component, precisely comprising of a pre-formed metal "hinge and locking" attachments in a single casting - a "hinge", "gate" and "clasp" [5].

The idea of "gate clasp" was suggested by Ackerman in 1955 in relation to mandibular defects [6] and was introduced by Simmons in the early 1960s [7]. A unique value of the swing lock design for patients having undergone maxillary or mandibular resective surgeries lies in the controlled direct mechanical retention and stabilization provided by the labial bar. Reciprocation is achieved via a palatal or lingual plate that contacts all of the remaining teeth on or above the height of contour. The cast palatal or lingual major connector is maximally extended for maximum support and resistance to occlusal forces on the non defect contralateral side. Occlusion on the side involving defect is designed to be light, so as to minimize the rotation of the prosthesis around the midline and into the defect. Direct retention is further aided by small vertical struts (similar to I-bar design), that traverses the marginal gingiva, and contacts the gingival third of abutment teeth [8].

The above described classical framework of swing lock cast partials addresses an optimal modality of treatment in surgically resected cases of head and neck carcinomas, by its ability to carefully regulate the distribution of stresses to multiple abutments in several planes, which thereby, allows control of rotational forces, especially when a non linear framework design is formulated.

However, there exist few flaws in its basic designing as well. Firstly the unaesthetic display of metal in the labial framework and the nature of its excessive rigidity has marred down its clinical acceptance amongst the patients. Also the hinge-latch locking

mechanism in a conventional SL-RPD undergoes noticeable wear and tear with time, leading to gradual loosening, and ultimately failure of the snap-lock mechanism [9,10].

Considering these indigenous drawbacks in conventional swing lock cast partials design and for patient's aesthetic concern, modifications in the classical design was done in this case; firstly the ideology to inculcate a flexible element in the framework was harped upon, that prompted incorporation of durable and aesthetically competent thermoplastic resin systems like polycarbonates, polyamides, polynylons, polyformaldehydes etc, of which the latter one, popularly known as Acetal or Thermoflex was used in this particular case, as it is touted as an exciting prospect amongst prosthodontists. Secondly hinge and latch locking mechanisms were not incorporated in the design, owing to its technique sensitive fabrication and operational mechanism, rather Acetal resin was made to adhere with the rest of metal framework, in the form of "wrap around" retainer design by mechano-chemical means, that imparted a "bracing effect" for further enhancement of retention to sound levels and ensured smooth insertion and removal of prosthesis on patient's part.

Thermoplastic Acetals, also known as Polyoxymethylene derived from formaldehyde, has been in use since 1986 and can be a good alternative to the metal in cast partial denture [11]. The choice of thermoplastic Acetal resin in the case is backed by its several advantageous mechanical properties namely strength, resistance against warpage and fractures, inherent flexibility, reduced residual monomer content, thereby, reducing the allergic concerns [12]. Furthermore by virtue of its high magnitude of impact resistance, it has an added shock absorption mechanical advantage. Dual benefits of its high Young's modulus of elasticity and resoundingly well aesthetics with chemical inertness have widely popularized its clinical applications amongst clinicians [13,14]. DuraCetal is available in 22 teeth and tissue shades, matched to standard vita shade guide [15].

Exploratory studies in the past have also highlighted the advantages of Acetal resins over metal alloys. One such study conducted by Wu JE et al., [16] compared the modulus of elasticity of Acetal resin (2.9-3.5 kN/mm²) with that of Cr-Co alloy (22.43kN/mm²). His study suggested that Acetal resin has superior flexibility which allows its use in larger retentive undercuts such as in inter-proximal area.

However, few disadvantages of Acetal resins are needed to be accounted as well. One such disadvantage is to include a greater thickness of material required compared to metal clasps due to its lowered flexural modulus which can cause plaque accumulation and affect gingival and periodontal health, so patient should be encouraged for hygiene maintenance [17]. Besides, in the process of imbibing its various hues, acrylic fibres are added to the matrix, that reduce the strength and resistance of the white range of shades, as compared to the pink counterparts [18].

CONCLUSION

When utilized effectively, the Swing lock partial dentures although an old concept, with suitable modifications in its classical design

parameters, can ease and enable prosthodontists to treat challenging clinical cases through a simple non cumbersome way out, while avoiding the more invasive and expensive treatment modalities, because comprehensive restoration of extensive defects of the oral cavity is certainly within the purview of trained maxillofacial prosthodontists.

In this narrated case with Cantor and Curtis type 4 mandibular defect, an effectively designed modified Swing lock cast partial denture prosthesis with a flexible arc of Acetal labial bar, instead of the conventional hinge and latch locking, mimicking an orthodontic "wraparound" retainer, in harmonious accordance with its neighbouring tissues, can foster with the much needed optimization of retention, stability and aesthetic requirements, that altogether constitute a comprehensive maxillofacial rehabilitation, thereby, playing a pivotal role towards upliftment of patient's overall quality of life.

REFERENCES

- [1] Cantor R, Curtis TA. Prosthetic management of edentulous mandibulectomy patients. I. Anatomic, physiologic, and psychologic considerations. *J Prosthet Dent.* 1971;25:446-57.
- [2] Akki SF, Rao S. Functional impression for hemimandibulectomy cases: An alternative technique. *International Journal of Prosthodontics and Restorative Dentistry.* 2011;1(2):115-7.
- [3] Mundhe K, Pruthi G, Jain V. Prosthodontic rehabilitation of patient with marginal mandibular resection using attachment supported prostheses: A clinical report. *Contemp Clin Dent.* 2014;5(1):123-126.
- [4] ITW Illinois Tool Works Inc. Plexus guide to bonding plastics-composites-metals. Available from: http://www.itwplexus.com/UserFiles/File/Guide_To_Bonding.
- [5] Lynch CD, Allen PF. The swing-lock denture: Its use in conventional removable partial denture prosthodontics. *Dental update.* 2004;31(9):506-8.
- [6] Ackerman AJ. The prosthetic management of oral and facial defects following cancer surgery. *J Prosthet Dent.* 1955;5(3):413-32.
- [7] Simmons JJ. Swinglock stabilization and retention. A preliminary clinical report. *Tex Dent J.* 1963;81:10-2.
- [8] Parr GR, Gardner LK. Swing-lock design considerations for obturator frameworks. *J Prosthet Dent.* 1995;74(5):503-11.
- [9] Schwalm CA, LaSpina FV. Fabricating swinglock removable partial denture frameworks. *J Prosthet Dent.* 1981;45:2216-20.
- [10] Becker CM, Bolender CL. Designing swinglock partial dentures. *J Prosthet Dent.* 1981;46:126-32.
- [11] Turner JW, Radford DR, Sherriff M. Flexural properties and surface finishing of Acetal resin denture clasps. *J Prosthodont.* 1999;8(3):188-95.
- [12] Phoenix RD, Mansueto MA, Ackerman NA, Jones RE. Evaluation of mechanical and thermal properties of commonly used denture base resins. *J Prosthet Dent.* 2004;13(1):17-27.
- [13] Forschirm A, Mc Andrew FB. *The Polymeric Materials Encyclopedia.* vol 1. London: England CRC Press; 1996. Acetal resins, in J.C. Salamone (ed) pp. 6-12.
- [14] Masamoto J. *The Polymeric Materials Encyclopedia.* vol 1. London, England: CRC. Press; 1996. Acetal Resins (homopolymers, copolymers and block polymers) in J.C. Salamone(ed) pp. 12-20.
- [15] Myerson DuraCetalTM Cosmetic Appliances. Available from: <http://www.myersonsotooth.com/products/dura-cetal.php>
- [16] Wu JC, Latta GH, Wicks RA, Swords RL, Scarbecz M. In-vitro deformation of acetyl resin and metal alloy removable partial denture direct retainers. *J Prosthet Dent.* 2003;90(6):586-90.
- [17] Fitton JS, Davies EH, Howlett JA, Pearson GJ. The physical properties of a polyacetal denture resin. *Clinical Materials.* 1994;17(3):125-9.
- [18] Chow TW, Ladizesky NH, Clarke DA. Acrylic resins reinforced with woven highly strain linear polyethylene fibres: Water sorption and clinical trials. *Aust Dent J.* 1992;37(6):433-38.

PARTICULARS OF CONTRIBUTORS:

1. Professor and Head, Department of Prosthodontia, Government Dental College and Hospital, Ahmedabad, Gujarat, India.
2. Professor, Department of Prosthodontia, Government Dental College and Hospital, Ahmedabad, Gujarat, India.
3. Postgraduate Student, Department of Prosthodontia, Government Dental College and Hospital, Ahmedabad, Gujarat, India.
4. Postgraduate Student, Department of Prosthodontia, Government Dental College and Hospital, Ahmedabad, Gujarat, India.
5. Postgraduate Student, Department of Prosthodontia, Government Dental College and Hospital, Ahmedabad, Gujarat, India.

NAME, ADDRESS, E-MAIL ID OF THE CORRESPONDING AUTHOR:

Dr. Vishal Bipinbihari Verma,
Postgraduate Student, Department of Prosthodontia, Government Dental College and Hospital, Ahmedabad-380016, Gujarat, India.
E-mail: vishal2689126@rediffmail.com

FINANCIAL OR OTHER COMPETING INTERESTS: None.

Date of Submission: Jul 16, 2016
Date of Peer Review: Sep 14, 2016
Date of Acceptance: Oct 10, 2016
Date of Publishing: Jan 01, 2017